



PATIENT

Preta Brito

SPECIES

Feline

BREED

DSH

SEX

Female Spayed

AGE

18 years

WEIGHT

5.4

INTERPRETED BY

Maggie Machen Lamy,
DVM, DACVIM
(Cardiology)

IMAGING PERFORMED BY

Hesham Akbawy, DVM

HOSPITAL NAME

Lincoln Avenue Cat
and Dog Hospital

REFERRING VET

Dr. Hesham Akbawy

INVOICE

47390

DATE

3/31/26

PRESENTING CLINICAL SIGNS

History: Has pitting edema on the back lower extremities. High creatinine (2.5), Normal RBCs, Low MCV, Low MCH, Low Reticulocyte. Elevated BNP: 1,068. BP: 151mmHg.

ECHOCARDIOGRAM FINDINGS

2D, m-mode, color flow and doppler imaging is available. The left ventricular wall is normal in dimension. There is a mildly hyperechoic endocardium consistent with mild fibrosis. The endocardium also appears mildly remodeled. The papillary muscles are normal in size and hyperechoic. The left atrium is normal in size. The right atrium is normal in size. The right ventricle appears normal. The mitral valve is normal in structure and mobility. No obvious valve regurgitation. Blood flow through both the LVOT and RVOT is normal in velocity. No pleural or pericardial effusion seen. No obvious cardiac tumors.

CARDIAC CHART

FELINE CARDIAC PARAMETERS	BODY WEIGHT	HR (BPM)	IVSd (cm) (Moise, Pipers)	LVIDd (cm) (Moise, Pipers)	LVWd (cm) (Moise, Pipers)	FS (%)	EF (%)
NORMAL PARAMETER	-----	150-240	0.35-0.55	<2 (mean 1.5)	3.5-0.55	35-67	80-100
PATIENT	5.4	NM	0.45	1.3	0.45	58	90
FELINE CARDIAC PARAMETERS	LA/AO (Boon)	LA/AO HEART BASE (Swe) (Abbott)	LA 2D short axis Base view (cm) (Abbott)	LVOT VEL (m/s)	RVOT VEL (m/s)	E max (m/s)	
NORMAL	<1.5	<1.3	<1.2	<1.6	<1.3	<0.9	
PATIENT	NM	1.3	1.2		0.8	NM	

**Note: All measurements based upon multi-modal images and methods. An average value is reported.*
 Adapted from June Boon, Veterinary Echocardiography, 1998
 Abbott J & MacLean H JVIM 2006;20: 111-119, Moise et al. Am J Vet Res 47:1476, 1986. Pipers et al. Am J Vet Res 40:882, 1979.

INTERPRETATION OF THE FINDINGS & FURTHER RECOMMENDATIONS

Overtly normal geriatric cardiac structure and function. The LV wall thickness is normal, and there is no evidence of elevated left atrial pressure or underlying pathology at this time. There is mild remodeling and fibrosis of the left ventricular wall, which is considered likely a normal age-related finding. Flow through the great vessels is normal, and no significant valve regurgitation is identified.

These findings would suggest pitting edema is noncardiogenic in origin.

Given these findings, no medications are indicated. Prognosis is good.

No obvious structural cause for BNP elevation is seen here. A flaw of the BNP test is false positives, which may be the case, given that hypertension and renal disease have been ruled out.



PATIENT

Preta Brito

SPECIES

Feline

BREED

DSH

SEX

Female Spayed

AGE

18 years

WEIGHT

5.4

INTERPRETED BY

Maggie Machen Lamy,
DVM, DACVIM
(Cardiology)

IMAGING PERFORMED BY

Hesham Akbawy, DVM

HOSPITAL NAME

Lincoln Avenue Cat
and Dog Hospital

REFERRING VET

Dr. Hesham Akbawy

INVOICE

47390

DATE

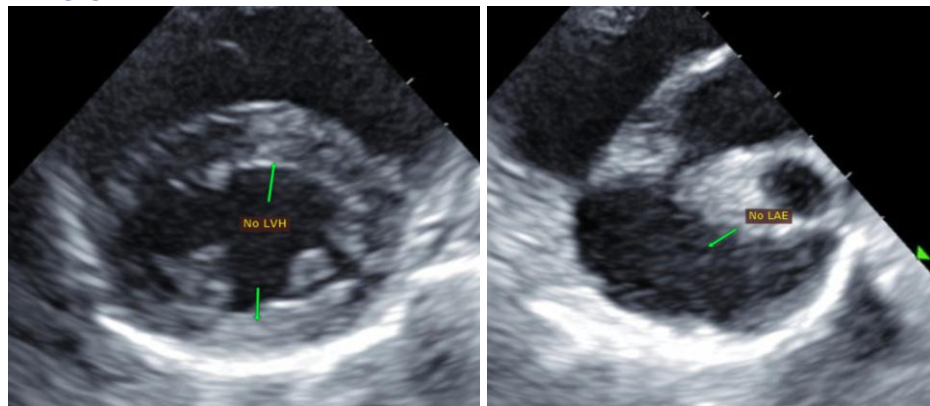
3/31/26

A thyroid level should be assessed. If no obvious cause is identified, reassessing this patient in 6-12 months is recommended to ensure early disease was not missed.

Anesthetic risk is considered mild. Risk for complication with steroid use or fluid administration typically follows LA dilation, which in this case is low. That being said, any cat can experience unexpected signs of intolerance and monitoring of RR/RE is advised particularly in the initiation phase.

Recommend recheck echocardiogram in 1 year to assess for any progressive issues.

IMAGES



The information and recommendations provided are based on the images presented by the referring veterinarian. No evaluation can be communicated regarding pathology that was not visible in the image/video clips provided.

Thank you for this referral. This report was generated using transcription software, and minor dictation errors may be present. If the clinical or image interpretation does not parallel your findings or if I can be of any further assistance, please contact me.

Maggie Machen Lamy, DVM
Diplomate of the American College of Veterinary Internal Medicine (Cardiology)
info@sonopath.com